



## Therapeutic Effects of Propolis, Royal jelly, Ostrich oil, and Aloe Vera on Cutaneous Leishmaniasis Lesions in a Laboratory Model

Mohsen Mahmoudi<sup>1</sup>, Sedigheh Saberi<sup>2</sup>, Parham Manouchehri<sup>3</sup>, Mehdi Mohebali<sup>4</sup>, Mahbobeh Parsaeian<sup>5</sup>, Zahra Hesari<sup>6</sup>, Marjan Seratnahaei<sup>7</sup>, Helia Behrouzfar<sup>8</sup>, Alireza Zahraei-Ramazani<sup>9\*</sup>

<sup>1</sup> Department of Parasitology and mycology, School of Public Health, Tehran University of Medical Sciences, Tehran, Iran. & lecturer in; the Department of Parasitology and mycology, School of medicine, Iran University of Medical Sciences, Tehran, Iran. <https://orcid.org/0000-0003-3256-8883>. Email: mmahmoodi45@gmail.com

<sup>2</sup>Department of Parasitology & Mycology, Faculty of medicine, Esfahan University of Medical Sciences, Esfahan, Iran. Email: sedisaberi@yahoo.com

<sup>3</sup>Biomedical Research Centre, University of Salford, Greater Manchester, England. Email: manouchehri@magfa.com

<sup>4</sup>Department of Parasitology and mycology, School of medicine, Iran University of Medical Sciences, Tehran, Iran. Email: mohebali37@yahoo.com

<sup>5</sup>Department of Epidemiology and Biostatistics. School of Public Health, Tehran University of Medical Sciences, Tehran, Iran. Email: mahbobehparsaeian@yahoo.com

<sup>6</sup>Department of Pharmaceutics, School of Pharmacy, Gilan University of Medical Sciences, Rasht, Iran. Email: z.hesari@gmail.com

<sup>7</sup> Ph.D. student, Department of Microbiology, North Tehran Branch, Islamic Azad University, Tehran, Iran. Email: marjan.nahaei@gmail.com

<sup>8</sup>Faculty of Specialized Veterinary Sciences, Science and Research Branch, Islamic Azad University, Tehran, Iran. Email: helia.behrouzfar@srbiau.ac.ir

<sup>9</sup>Department of Medical Entomology & Vector Control, School of Public Health, Tehran University of Medical Sciences, Tehran, Iran. Email: alirezazahraei@yahoo.com

### Article Info

Received 16/10/2022

Received in revised form

30/11/2022

Accepted 07/01/2023

### Keywords:

Leishmaniasis, Propolis,

Royal Jelly,

Ostrich Oil,

Aloe Vera

### Abstract

In recent decades, effective herbal and natural compounds have been formulated with topical application, reduced side effects, and more economic benefits for Cutaneous Leishmaniasis (CL) treatment. Some of these include Propolis, Royal jelly, Ostrich oil, and Aloe Vera, which have widespread use in health products. The study aimed to evaluate the potential therapeutic effects of a prepared topical combination, including Propolis, Royal jelly, Ostrich oil, and Aloe Vera, on *Leishmania major* lesions under an in vivo model in BALB/c (concatenation of Bagg and Albino) mice. Fifty BALB/c mice were randomly divided into five groups of ten. CL lesions were induced by inoculation of metacyclic promastigotes at the base of the BALB/c mice's tails. The resulting lesions were treated topically with prepared natural combinations of Propolis, Royal jelly, Ostrich oil, and Aloe Vera. The lesion sizes were determined as the mean  $\pm$  standard deviation. One-way analysis of variance (ANOVA) with the Bonferroni correction method was used for statistical analysis, with  $p < 0.05$  considered statistically significant. Based on the data of this research, comparative ulcer size reductions were 63.4% ( $3.25 \text{ mm} \pm 0.24$ ), 68.4% ( $3.55 \text{ mm} \pm 0.22$ ), and 8.5% ( $0.44 \text{ mm} \pm 0.98$ ) for the natural combination treatment 1, treatment 2, and Glucantime, respectively. Based on the results, the proposed natural combinations were significantly more effective at reducing ulcer size than Glucantime, the standard drug ( $p < 0.05$ ). Collectively, we conclude that a combination consisting of Propolis, Royal jelly, Aloe Vera, and ostrich oil is effective in treating CL in mice and may provide a new agent in the treatment of Leishmaniasis.

\*Corresponding author. Tel: +9802142933035, Fax: 02142933111,

E-mail address: alirezazahraei@yahoo.com

DOI: 10.22104/ARMMT.2023.5903.1079

## 1. Introduction

Cutaneous leishmaniasis (CL), associated with considerable morbidity, remains a serious health problem in many countries, especially in developing ones. The worldwide incidence of cutaneous leishmaniasis is approximately 1.5 million cases annually (Badirzadeh et al., 2022). Cutaneous leishmaniasis is endemic in the countries of the globe's tropics and subtropics region (Badirzadeh et al., 2022). The most common form is cutaneous leishmaniasis (CL), which can be caused by several *Leishmania* spp and is rarely fatal. *Leishmania tropica* (*L. tropica*) is the causative agent of anthroponotic cutaneous leishmaniasis (ACL), while *L. major* causes zoonotic cutaneous leishmaniasis (ZCL) (Bamorovat et al., 2021). For many decades, pentavalent antimony has remained the gold-standard therapeutic agent for various forms of leishmaniasis treatment. Literature indicates that treatment with chemical compounds such as Glucantime, Amphotericin B, and Miltefosine (hexadecylphosphocholine) has been associated with unfavorable side effects, such as localized pain after injection, stiff joints, gastrointestinal complications, cardiotoxicity, and drug resistance, especially in endemic areas (Aronson et al., 2016). Some innovative therapies, such as the lipid formulations of amphotericin B, are extremely expensive. This cost is the greatest factor that affects people with leishmaniasis in the developing world. Therefore, it is critical to rapidly develop and produce new antileishmanial medicines (Meena et al., 2010).

In addition, in recent years, scientists have explored natural materials in an effort to find alternatives to the highly toxic chemicals that are often used as antileishmanial medication. Some of these materials include Propolis, Royal jelly, Aloe Vera, and Ostrich oil. Propolis is a brownish substance obtained by honeybees from flowers, leaves, bark, and other parts of perennial plants such as Willow, Sycamore, Pine, Poplar, and Indian oak (Silici and Kutluca, 2005). Studies on pathogenic fungi indicate that propolis has inhibitory and fatal effects on fungal diseases,

especially in the candidates (Fernandes Jr et al., 1995; SFORCIN et al., 2001; Diba et al., 2010). Recent studies have also confirmed the role of propolis in protozoan diseases such as trichomoniasis, toxoplasmosis, and leishmaniasis, amongst others (Mahmoudi et al., 2009; Shirani-Bidabadi et al., 2009; Nilforoushzadeh et al., 2008; Saberi et al., 2013, Sena-Lopes et al., 2018; Kiderlen et al., 2001). Several studies have demonstrated that propolis inhibits the growth of at least 21 bacterial species (MRSA), including Gram-positive bacteria and a wide range of viruses (Grange and Davey, 1990; Brown et al., 2016; Noori et al., 2012). The effect of propolis is likely stimulation of the cytotoxic activity of natural killer cells (Sforcin et al., 2002, Takeda et al., 2018). In addition, propolis has a number of immunochemical effects, such as stimulating the humoral and cellular immune systems, anesthetizing, acting as a natural antioxidant and anti-inflammatory, strengthening soft connective tissues, and inhibiting the activity of several hydrolases and oxidoreductase. In addition, propolis provides antioxidant properties in the preservation of food (Ahn et al., 2004; Marquele et al., 2005).

Royal jelly is a concentrated milky liquid consisting of 67% water, 12.5% protein, 11% sugar, and 5% acids, vitamins, enzymes, antibacterial compounds, and antibiotics (Weaver & Weaver, 2003). There is evidence that this substance has antioxidant, antitumor, antimicrobial, and neurogenesis properties (Nakaya et al., 2007; Ito et al., 2012; Park et al., 2012; Hattori et al., 2007; Maenthaisong et al., 2007). Aloe Vera is a herb with proven healing and therapeutic effects. It has antibacterial (*Escherichia coli*, *Pseudomonas aeruginosa*, *Staphylococcus aureus*, *Salmonella typhi*) and antifungal (Aspergillosis, *Candida* species, and *Penicillium* species) effects (Shahzad & Ahmed, 2013; Marimuthu Alias Antonisamy et al., 2012; Ahmed et al., 2016; Farahnejad et al., 2012). This material has boosting and regulatory effects on the immune system (Farahnejad et al., 2012). Finally, ostrich oil consists of high levels of essential fatty acids. Since the molecules of ostrich oil are very similar to those of human skin, they are rapidly and deeply

absorbed between the layers of the skin, enabling the skin to be repaired and strengthened. This medicine's effect on injured human skin is noticeably faster than that of other drugs (Zemstov et al., 1996; Liu et al., 2013). According to the type of skin, the depth of the skin layers, and the weight of the affected individual, ostrich oil can be beneficial in reducing the symptoms of skin diseases, including eczema and psoriasis. The product can also be used for reducing skin aging, pancreatitis, radioprotective burns, toe fungus, foot cracks, and sunburns, fixing cracks and stains during pregnancy, and removing skin sensitivity (Mashtoub, 2017; Afshar et al., 2016; Lopez et al., 1999; Attarzadeh et al., 2013).

The purpose of this study was to determine the topical effects of a combination of Propolis, Royal jelly, Aloe Vera, and Ostrich oil on *L. major* skin lesions in BALB/c mice. We want to evaluate and introduce a low-cost, safe, and economical way of treating CL lesions via an effective combination therapy to improve human lesions caused by *L. major* without extensive scarring.

Cutaneous leishmaniasis (CL), associated with considerable morbidity, remains a serious health problem in many countries, especially in developing ones. The worldwide incidence of cutaneous leishmaniasis is approximately 1.5 million cases annually (Badirzadeh et al., 2022). Cutaneous leishmaniasis is endemic in the countries of the globe's tropics and subtropics region (Badirzadeh et al., 2022). The most common form is cutaneous leishmaniasis (CL), which can be caused by several *Leishmania* spp and is rarely fatal. *Leishmania tropica* (*L. tropica*) is the causative agent of anthroponotic cutaneous leishmaniasis (ACL), while *L. major* causes zoonotic cutaneous leishmaniasis (ZCL) (Bamorovat et al., 2021). For many decades, pentavalent antimony has remained the gold-standard therapeutic agent for various forms of leishmaniasis treatment. Literature indicates that treatment with chemical compounds such as Glucantime, Amphotericin B, and Miltefosine (hexadecylphosphocholine) has been associated with unfavorable side effects, such as localized pain after injection, stiff joints, gastrointestinal

complications, cardiotoxicity, and drug resistance, especially in endemic areas (Aronson et al., 2016). Some innovative therapies, such as the lipid formulations of amphotericin B, are extremely expensive. This cost is the greatest factor that affects people with leishmaniasis in the developing world. Therefore, it is critical to rapidly develop and produce new antileishmanial medicines (Meena et al., 2010).

In addition, in recent years, scientists have explored natural materials in an effort to find alternatives to the highly toxic chemicals that are often used as antileishmanial medication. Some of these materials include Propolis, Royal jelly, Aloe Vera, and Ostrich oil. Propolis is a brownish substance obtained by honeybees from flowers, leaves, bark, and other parts of perennial plants such as Willow, Sycamore, Pine, Poplar, and Indian oak (Silici and Kutluca, 2005). Studies on pathogenic fungi indicate that propolis has inhibitory and fatal effects on fungal diseases, especially in the candidates (Fernandes Jr et al., 1995; SFORCIN et al., 2001; Diba et al., 2010). Recent studies have also confirmed the role of propolis in protozoan diseases such as trichomoniasis, toxoplasmosis, and leishmaniasis, amongst others (Mahmoudi et al., 2009; Shirani-Bidabadi et al., 2009; Nilforoushzadeh et al., 2008; Saberi et al., 2013, Sena-Lopes et al., 2018; Kiderlen et al., 2001). Several studies have demonstrated that propolis inhibits the growth of at least 21 bacterial species (MRSA), including Gram-positive bacteria and a wide range of viruses (Grange and Davey, 1990; Brown et al., 2016; Noori et al., 2012). The effect of propolis is likely stimulation of the cytotoxic activity of natural killer cells (Sforcin et al., 2002, Takeda et al., 2018). In addition, propolis has a number of immunochemical effects, such as stimulating the humoral and cellular immune systems, anesthetizing, acting as a natural antioxidant and anti-inflammatory, strengthening soft connective tissues, and inhibiting the activity of several hydrolases and oxidoreductase. In addition, propolis provides antioxidant properties in the preservation of food (Ahn et al., 2004; Marquele et al., 2005).

Royal jelly is a concentrated milky liquid consisting of 67% water, 12.5% protein, 11% sugar, and 5% acids, vitamins, enzymes, antibacterial compounds, and antibiotics (Weaver & Weaver, 2003). There is evidence that this substance has antioxidant, antitumor, antimicrobial, and neurogenesis properties (Nakaya et al., 2007; Ito et al., 2012; Park et al., 2012; Hattori et al., 2007; Maenthaisong et al., 2007). Aloe Vera is a herb with proven healing and therapeutic effects. It has antibacterial (*Escherichia coli*, *Pseudomonas aeruginosa*, *Staphylococcus aureus*, *Salmonella typhi*) and antifungal (Aspergilliosis, *Candida* species, and *Penicillium* species) effects (Shahzad & Ahmed, 2013; Marimuthu Alias Antonisamy et al., 2012; Ahmed et al., 2016; Farahnejad et al., 2012). This material has boosting and regulatory effects on the immune system (Farahnejad et al., 2012). Finally, ostrich oil consists of high levels of essential fatty acids. Since the molecules of ostrich oil are very similar to those of human skin, they are rapidly and deeply absorbed between the layers of the skin, enabling the skin to be repaired and strengthened. This medicine's effect on injured human skin is noticeably faster than that of other drugs (Zemstov et al., 1996; Liu et al., 2013). According to the type of skin, the depth of the skin layers, and the weight of the affected individual, ostrich oil can be beneficial in reducing the symptoms of skin diseases, including eczema and psoriasis. The product can also be used for reducing skin aging, pancreatitis, radioprotective burns, toe fungus, foot cracks, and sunburns, fixing cracks and stains during pregnancy, and removing skin sensitivity (Mashtoub, 2017; Afshar et al., 2016; Lopez et al., 1999; Attarzadeh et al., 2013).

The purpose of this study was to determine the topical effects of a combination of Propolis, Royal jelly, Aloe Vera, and Ostrich oil on *L. major* skin lesions in BALB/c mice. We want to evaluate and introduce a low-cost, safe, and economical way of treating CL lesions via an effective combination therapy to improve human lesions caused by *L. major* without extensive scarring.

## 2. Materials and methods

### 2.1. Preparation, reproduction, and maintenance of the parasitic culture media

The standard strain of *L. major*, MRHO/IR/75/ER, was obtained from the Pasteur Institute of Tehran. First, the parasites (promastigote) were cultured in a biphasic NNN medium; subsequently, they were passaged and supplemented, at 25°C in RPMI1640 medium (PAA, Australia), with 10% inactivated fetal bovine serum (Sigma-Aldrich, USA), 100 U/ml penicillin, and 100 g/ml streptomycin.

### 2.2. Combination and preparation

The ingredients for the combination we developed include propolis hydroalcoholic extract, royal jelly, Aloe Vera gel, ostrich oil, and Eucerin as a cream base. A hydroalcoholic extract of propolis was prepared by the Esfahan Herbs Research Center. In this study, Eucerin was used as the base for the combination because, in addition to maintaining the strength and effect of the drug, it has less fat than petrolatum (Vaseline) and lanolin. A total of 13g of pure royal jelly was introduced into 8 g of ostrich oil and mixed thoroughly. Then, 11 g of pre-prepared Aloe Vera gel and 13 g of hydroalcoholic propolis extract were added. All the ingredients, along with 55 g of Eucerin, were placed in a hot plate magnet and mixed at a speed of 100 rpm for 10 minutes. This combination was used in treatment group 1. In order to determine the possibility of the dependence of the cream's effect on the concentration of the components, a second cream with lower concentrations was prepared for 'treatment group 2'. The combination for treatment group 2 consisted of 7 g of royal jelly, 7 g of hydroalcoholic propolis extraction, 6 g of Aloe Vera gel, 5 g of ostrich oil, and 75 g of pure Eucerin prepared as described above (Zahedifard et al., 2020; Dantas Silva et al., 2017). Fifty BALB/c mice weighing 26-28g and aged 8-9 weeks were selected and examined.

Considering the ethical standards of working with mice, the BALB/c Mice were treated according to the "Guidelines for the Intensity of Interventions in Laboratory Animals" set by the

Ministry of Health and Medical Education of Iran (<http://ethics.research.ac.ir>). The mice were inoculated with the standard strain of *L. major* (MRHO/IR/75/ER) subcutaneously at the base of the tails. At least  $3 \times 10^6$  metacyclic promastigotes (0.5 ccs), harvested at the stationary phase of culture, were inoculated. After three weeks, nodules appeared around the injected areas on all 50 inoculated mice.

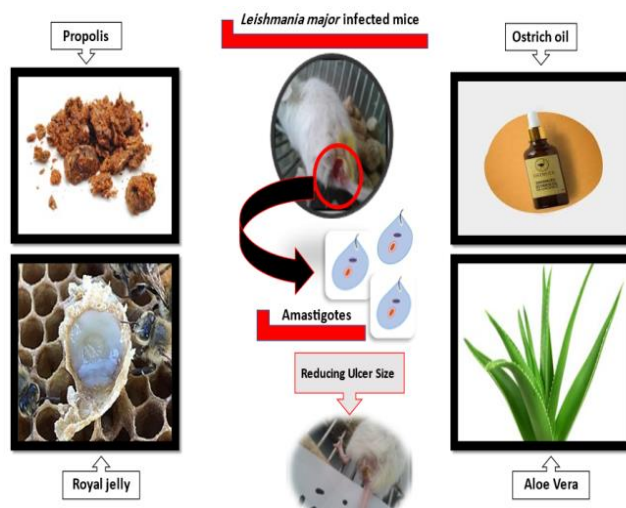
### 2.3. Groups design

The mice were divided into five experimental groups. The groups with CL were treated as follows: the first and second groups with the naturally prepared combinations; the third group with the drug base (Eucerin); the fourth group with the standard drug, Glucantime; and the fifth group as a control group without any medication. Prior to the start of treatment, the diameter of each mouse's nodule or lesion was measured with a Vernier caliper. The modules or lesions were remeasured every two weeks for 12 weeks. At the beginning and end of the study, impression smears were prepared from each mouse's lesions, fixed with pure methanol, and stained with Giemsa; the parasitology was then examined by a light microscope (100x), the golden standard.

### 2.4. In vivo stage

An in vivo survey was performed on the 50 BALB/c Mice. The mice in the treatment groups received the natural combination at two different concentrations for 30 days. The mice received two applications daily by rubbing the cream on the local lesions, one in the morning and one in the evening. In the third group, the Eucerin-based treatment group, Eucerin was similarly applied twice a day. In the fourth group, Glucantime was administered intraperitoneally to infected mice as standard medication for 30 days. The fifth group was the control group that did not receive any treatment interventions. After 30 days, in the middle and at the end of treatment, the diameter of the lesions was remeasured with a Vernier caliper in all mice and recorded. A re-sampling was also carried out. The specimens were fixed and stained, then parasitological examinations were conducted

by light microscopy (100x). In each of the three stages, the number of amastigotes in each field of vision was recorded. Mupirocin was considered to prevent secondary infection (Fig 1).



**Figure 1.** Combination consisting of Propolis, Royal jelly, Aloe Vera, and Ostrich oil in CL infected mice

The results were analyzed using the repeated measures ANOVA statistical test, and the Bonferroni correction method was employed to adjust for multiple comparisons. Then, a comparison of the means (LSD) test was used to evaluate the significance of the difference between the different groups. Lastly, the comparison of the means was analyzed. All statistical analyses were conducted by Stata software (Version 12), and *p*-values of less than 0.05 were considered significant

### 3. Results and discussion

An evaluation of the lesion size is one of the most reliable parameters for monitoring the effects of drug treatment. As shown in Figure 2, treatments 1 and 2 significantly decreased the lesion's diameter ( $p < 0.05$ ), with the lesion size tilting to nearly zero at the end of the treatment. As seen in Figure 2, this decreasing trend began accelerating in the second week. No statistically significant difference was found between treatment groups 1 and 2 ( $p > 0.05$ ) (Table 1). The two concentrations of this compound exhibited almost identical results in terms of the effect of the treatment on mouse lesions. Today, efforts

continue to find an appropriate, effective, economical, and accessible method with minimal side effects to treat leishmaniasis. The significant therapeutic effect of propolis or its hydroalcoholic extract on CL has been demonstrated in previous studies (Mahmoudi et al., 2009; Shirani-Bidabadi et al., 2009).

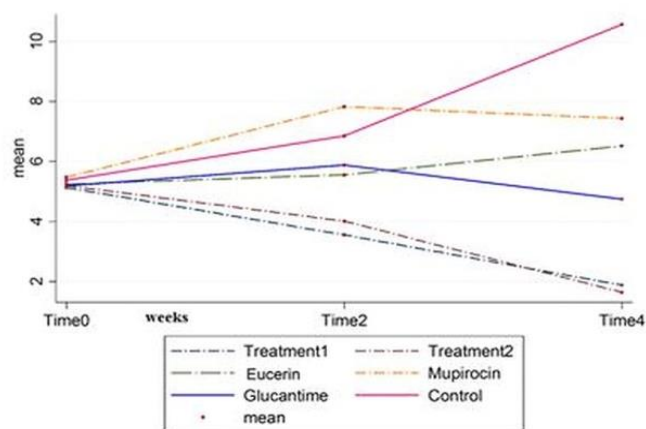
In contrast, the use of Eucerin alone as a cream base was accompanied by a slight increase in the size of the lesions until the second week, after which it increased significantly until the fourth week (Fig 2). A statistically significant decrease in the size of lesions was observed in the treatment groups compared to the Eucerin group ( $p < 0.05$ ) (Table 1).

**Table 1.** The result of multiple comparisons

Comparison between Treatments	<i>p</i> -value
Eucerin and treatment group 1	0.0065
Eucerin and treatment group 2	0.0052
Treatment groups 1,2	0.4849
Mupirocin and treatment 1	0.0000
Mupirocin and treatment 2	0.0000

Recently, it was reported that the ethanolic extract of propolis (EEP) has an anti-leishmanial effect against *L. major* in vitro and in vivo, and the difference between EEP and Glucantime was not significant (Tavakoli et al., 2020). Furthermore, another study demonstrated that very low concentrations of propolis caused changes in the morphological structure of the parasites and were more effective than the other bee products (Aksoy et al., 2020). Also, the effects of standardized BGP hydroalcoholic extract as a therapeutic adjuvant to treat cutaneous leishmaniasis caused by *L. amazonensis* has been shown (Cunha et al., 2020). Regarding the secondary treatment with Mupirocin, the lesion size increased significantly until the second week of treatment. In the following two weeks, however, we observed a slight and gradual reduction in the magnitude of the lesion, contrasting with the effects of treatment with Eucerin (Fig 2). Generally, mice die during in vivo CL studies due to a secondary infection or the migration of parasites into the viscera. By

preventing a secondary infection, Mupirocin allowed the focal treatment to progress along its natural pathway. A significant difference was observed between the effects of treatment with natural compounds accompanied by Mupirocin on the reduction of lesion size ( $p < 0.05$ ) (Table 1). In Figure 3, changes in lesion size over four weeks are compared in relation to topical administrations.



**Figure 2.** Alterations in lesion size (mm) during the course of the administration of the combination treatment in comparison to the control groups, measured at the following time points Time 0: start of treatment Time 2: 2 weeks after starting point Time 4: 4 weeks after starting point

The effects of the two treatment groups, the Glucantime group, and the control group, can be compared in Table 2. The table shows the results of treatment with compounds 1 and 2 compared to Glucantime from the start until the last day of treatment (baseline and 4th week). As can be seen, both compounds 1 and 2 show greater efficacy in reducing the size of the ulcer than Glucantime. In addition, the experimental data on lesion size at the baseline in the initial stages of the study and after four weeks were summarized. The results showed that there were statistically significant differences ( $p < 0.05$ ) between the two groups in terms of lesion size reduction (Table 3).

As displayed in Table 2, the average lesion size in the control group increased significantly by 96.3% (5.18 mm). This was not the case following the application of Glucantime, which successfully

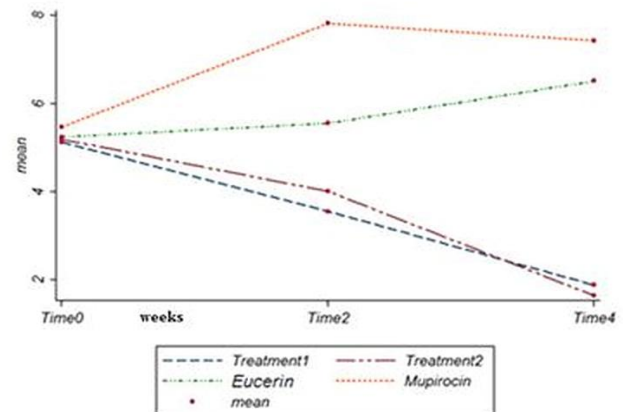
reduced the lesion size by 8.5% (0.44 mm) on average after four weeks. The focal treatment groups 1 and 2 reduced the lesion size by 63.4% (3.25 mm) and 68.4% (3.55 mm), respectively. After four weeks, treatment groups 1 and 2 were more effective in reducing the average lesion size than Glucantime, the standard drug. As shown in Table 3, the reduction in lesion size after administering the two natural treatment groups was statistically significant.

Aloe Vera is a distinctive herb with a beneficial capacity to aid skin wound healing in addition to antibacterial, antifungal, and anti-inflammatory properties (Shahzad & Ahmed, 2013; Marimuthu Alias Antonisamy et al., 2012; Ahmed et al., 2016). Recently, it was reported that Aloe Vera reduced the number of promastigotes in vitro, and an in vivo model demonstrated that Aloe Vera and Glucantime significantly decreased the size of ulcers in mice with cutaneous leishmaniasis (Hamid et al., 2019). They concluded that Aloe Vera controlled *L. major*. Another study showed that an herbal topical ointment including Aloe vera, *Perovskia abrotanoides*, *Nigella sativa*, propolis, lavender, and olive oil displayed significant in vivo antileishmanial activities and can be used as an alternative medicine in the treatment and healing of human CL lesions (Saber et al., 2021).

Ostrich oil is very effective in expediting wound healing. Researchers have investigated the anti-inflammatory and regenerative effects of this oil on second-degree burns in mouse models (Mashtoub, 2017; Afshar et al., 2016).

The standard treatment for leishmaniasis is currently Glucantime. However, due to its high cost and difficulty to access, as well as the unfavorable side effects and adverse drug reactions seen in patients, researchers are now seeking alternatives. Regarding the anti-inflammatory, regenerative, and antimicrobial properties of the above materials, it was decided to study a combination of these substances as a topical cream on CL and investigate its effect on the disease. It should be noted that the above substances are considered to be of diminutive

medical concern independently, and no reports of serious side effects have been noted.



**Figure 3.** Comparison of topical treatment groups relative to the duration of treatment and lesion size.

Time 0: start of treatment, Time 2: 2 weeks after starting point, Time 4: 4 weeks after starting point

As seen in (Fig 3), the size of lesions increased in both the treatment groups using Mupirocin and Eucerin. In the Mupirocin alone group, the wound size was moderately reduced after the second week of treatment. A possible justification for this outcome would be the manifestation of secondary infection, discounting one parasitic element. The ulcer consequently becomes increasingly inflamed and enlarged, and the infection ultimately alters the lesion's natural characteristics. However, in the Mupirocin treatment group, antibiotics prevent the development of secondary infection, and therefore, the morphology of the lesion remains natural. According to the literature, in the absence of antileishmanial treatment, the ulcer is spontaneously restricted, and the parasite migrates to the liver and spleen of the mouse, but the scar will remain. Mupirocin is a natural antibiotic that is produced by the fermentation processes of the *Pseudomonas fluorescens* strain and is effective against a wide range of bacteria, including *Streptococcus pyogenes* and *Staphylococcus aureus* strains (Nicholas et al., 1999; Poovelikunnel et al., 2015).

According to the findings, both natural combination treatment groups 1 and 2 significantly reduced lesion size and restored scar tissue after

ulcer healing. This suggests that natural focal combinations have been effective in controlling and treating lesions caused by *L. major*. Table 1 confirms the statistically significant difference between the treatment groups of Eucerin/Mupirocin with combinations 1 and 2 ( $p < 0.05$ ). A comparison of the two combinations of the same components at different concentrations revealed no statistically significant difference in terms of results ( $p > 0.05$ ), suggesting that the two combinations have a similar therapeutic effect. Due to the two compounds' relatively similar therapeutic effect, the use of combination 1 is more economically justifiable. Furthermore, the fat content of this compound is lower than that of combination 2.

**Table 2.** Average lesion size following lesion instigation at the baseline prior to treatment and in the fourth week of treatment following the topical application of combination for treatment groups 1, 2, and IP administration of Glucantime. Data for the unperturbed control group was provided to allow for evaluation.

Investigative Groups	Average lesion size at baseline (mm)	Average lesion size in the fourth week (mm)	Standard error of the mean (SEM)
Treatment 1	5.13	1.88	0.24
Treatment 2	5.19	1.64	0.22
Glucantime	5.18	4.74	0.98
Control	5.38	10.56	0.66

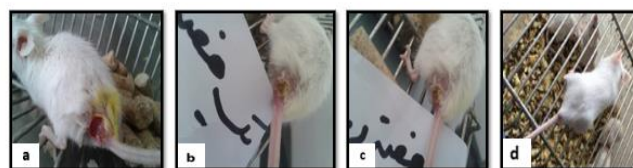In Table 2, the effect of Glucantime, the gold standard medication for the treatment of Leishmaniasis, was compared with drug compounds 1, 2, and the control group. As expected, the lesion's growth rate appeared to be on an increasing trend in the control group, but in the Glucantime group, the drug was able to relatively prevent the growth of the wound. However, environmental bacteria gradually infected the Leishmania lesions in mice. Most cases of death in mice are due to this secondary infection and its development. As shown in Tables 2 and 3, both natural combinations have a greater effect on the treatment of CL than Glucantime, and

there is a statistically significant difference between the two groups ( $p < 0.05$ ). Additionally, the side effects of these compounds are less severe, and they are easier to access than Glucantime.

**Table 3.** Comparison of lesion size between the control, treatment groups 1, 2 and Glucantime following statistical analysis.

Comparison of the average lesion size in the fourth week between treatment routes	t-test	p-value
Glucantime /Treatment 1	5.4	<0.0001
Glucantime/Treatment 2	5.9	<0.0001
Control/Treatment 1	22.3	<0.0001
Control/Treatment 2	23.4	<0.0001

Finally, samples were taken from the scar or the remaining lesions and stained to confirm the results. In the treatment group with the natural combination and treatment with Glucantime, most lesions and scars did not have *L. major* parasites, but they were positive in the other groups. According to our results, a combination of propolis, royal jelly, Aloe Vera, and ostrich oil is effective for the treatment of CL in mice (Fig 4).



**Figure 4.** Comparison of before and after treatment in BALB/c Mice.

a: Before treatment.

b: 1 week after treatment with the combination.

c: 2 weeks after treatment with the combination.

d: Control group

#### 4. Conclusion

Based on the results of this study, it appears that a combination comprising propolis, royal jelly, Aloe Vera, and ostrich oil is effective for the treatment of CL in mice. Therefore, we propose that the efficacy of these extracts could be evaluated alone or in combination against human



cutaneous leishmaniasis after obtaining permission and under the rules of the Ethics Committee for Research as a randomized clinical trial.

### Disclosure statement:

All authors report no conflict of interest.

### Funding:

The Tehran University of Medical Sciences supported this study.

### Conflict of Interest

The authors declare that they have no competing interests.

### Open access

This article distributed under the terms of the Creative Commons Attribution License which permits unrestricted use, distribution, and reproduction in any medium,

### Acknowledgments

The authors wish to appreciate the staff of Esfahan Health Research Station, Tehran University of Medical Sciences, for their kind collaboration in the Laboratory operation.

### References

[1] AFSHAR, M., GHADERI, R., ZARDAST, M. & DELSHAD, P. 2016. Effects of topical emu oil on burn wounds in the skin of Balb/c mice. *Dermatology Research and Practice*, 2016.

[2] AHMED, S., AHMAD, M., SWAMI, B. L. & IKRAM, S. 2016. A review on plants extract mediated synthesis of silver nanoparticles for antimicrobial applications: a green expertise. *Journal of advanced research*, 7, 17-28.

[3] AHN, M.-R., KUMAZAWA, S., HAMASAKA, T., BANG, K.-S. & NAKAYAMA, T. 2004. Antioxidant activity and constituents of propolis collected in various areas of Korea. *Journal of Agricultural and Food Chemistry*, 52, 7286-7292.

[4] AKSOY, T., SIVCAN, E., DOGAN, F., CETIN, S. and YAR, T.M. 2020. Investigation of anti-leishmanial effects of bee products (Honey, Propolis) on leishmania tropica promastigotes. *Mikrobiyoloji Bulteni*, 54(3), pp.479-489.

[5] ARONSON, N., HERWALDT, B. L., LIBMAN, M., PEARSON, R., LOPEZ-VELEZ, R., WEINA, P., CARVALHO, E. M., EPHROS, M., JERONIMO, S. & MAGILL, A. 2016. Diagnosis and treatment of leishmaniasis: clinical practice guidelines by the Infectious Diseases Society of America (IDSA) and the American Society of Tropical Medicine and Hygiene (ASTMH). *Clinical infectious diseases*, 63, e202-e264.

[6] ATTARZADEH, Y., ASILIAN, A., SHAHMORADI, Z. & ADIBI, N. 2013. Comparing the efficacy of Emu oil with clotrimazole and hydrocortisone in the treatment of seborrheic dermatitis: a clinical trial. *Journal of Research in Medical Sciences: The Official Journal of Isfahan University of Medical Sciences*, 18, 477.

[7] BADIRZADEH, A., NAJM, M., HEMPHILL, A., ALIPOUR, M., HASSANPOUR, H., MASOORI, L. and KARIMI, P. 2022. Effects of negative air ions (NAIs) on Leishmania major: A novel tool for treatment of zoonotic cutaneous leishmaniasis (ZCL). *PloS one*, 17, p.e0274124.

[8] BAMROVAT, M., SHARIFI, I., TAVAKOLI OLIAEE, R., JAFARZADEH A. and KHOSRAVI, A. 2021. Determinants of unresponsiveness to treatment in cutaneous leishmaniasis: a focus on anthroponotic form due to Leishmania tropica. *Frontiers in Microbiology*, p.1143.

[9] BROWN, H. L., ROBERTS, A. E. L., COOPER, R. & JENKINS, R. 2016. A review of selected bee products as potential anti-bacterial, anti-fungal, and anti-viral agents.

[10] CUNHA, B.C., DE MIRANDA, M.B., AFONSO, L.C.C., ABREU, S.R.L., TESTASICCA, M.C.D.S., DA SILVA, G.R. and DE MOURA, S.A.L. 2020. Brazilian green propolis hydroalcoholic extract as a therapeutic adjuvant to treat cutaneous leishmaniasis. *Journal of Applied Pharmaceutical Science*, 10, pp.124-132.

[11] DANTAS SILVA, R.P., MACHADO, B.A.S., BARRETO, G.D.A., COSTA, S.S., ANDRADE, L.N., AMARAL, R.G., CARVALHO, A.A., PADILHA, F.F., BARBOSA, J.D.V. and UMSZA-GUEZ, M.A. 2017. Antioxidant, antimicrobial, antiparasitic, and cytotoxic properties of various Brazilian propolis extracts. *PloS one*, 12, 172585.

[12] DIBA, K., MOUSAVI, B., MAHMOUDI, M. & HASHEMI, J. 2010. In-vitro anti fungal activity of Propolis alcoholic extract on Candida spp. and Aspergillus spp. *Tehran University Medical Journal*, 68.

[13] FARAHNEJAD, Z., GHAZANFARI, T. & NOORIFARD, M. 2012. Immunomodulatory effects of Aloe Vera on of the fungus Candida Albicans in animal model. *Annals of Military and Health Sciences Research*, 10.

[14] FERNANDES JR, A., SUGIZAKI, M., FOGO, M., FUNARI, S. & LOPES, C. 1995. In vitro activity of propolis against bacterial and yeast pathogens isolated from human infections. *Journal of venomous Animals and Toxins*, 1, 63-69.

[15] GRANGE, J. & DAVEY, R. 1990. Antibacterial properties of propolis (bee glue). *Journal of the Royal Society of Medicine*, 83, 159-160.

[16] SHAMSI, H., MINOO, S., YAKHCHALI, M., AKBARZADEH, M., RAOUFI, N., TAVAKOLI, M.,

- DASTGHEIB, M., DASTGHEIB, M. 2019. The antileishmanial activity of Aloe vera leaf exudates: in vitro and in vivo. *Iranian Journal of Dermatology*, 22, pp.18-24.
- [17] HATTORI, N., NOMOTO, H., FUKUMITSU, H., MISHIMA, S. & FURUKAWA, S. 2007. Royal jelly and its unique fatty acid, 10-hydroxy-trans-2-decenoic acid, promote neurogenesis by neural stem/progenitor cells in vitro. *Biomedical research*, 28, 261-266.
- [18] ITO, S., NITTA, Y., FUKUMITSU, H., SOUMIYA, H., IKENO, K., NAKAMURA, T. & FURUKAWA, S. 2012. Antidepressant-like activity of 10-hydroxy-trans-2-decenoic acid, a unique unsaturated fatty acid of royal jelly, in stress-inducible depression-like mouse model. *Evidence-Based Complementary and Alternative Medicine*, 2012.
- [19] KIDERLEN, A. F., KAYSER, O., FERREIRA, D. & KOLODZIEJ, H. 2001. Tannins and related compounds: killing of amastigotes of *Leishmania donovani* and release of nitric oxide and tumour necrosis factor  $\alpha$  in macrophages in vitro. *Zeitschrift für Naturforschung C*, 56, 444-454.
- [20] LIU, X., CHEN, T., LIU, X., CHEN, Y. & WANG, L. 2013. Penetration effect of ostrich oil as a promising vehicle on transdermal delivery of sinomenine. *Journal of oleo science*, 62, 657-664.
- [21] LOPEZ, A., SIMS, D. E., ABLETT, R., SKINNER, R., LEGER, L., LARIVIERE, C., JAMIESON, L., MARTÍNEZ-BURNES, J. & ZAWADZKA, G. 1999. Effect of emu oil on auricular inflammation induced with croton oil in mice. *American journal of veterinary research*, 60, 1558-1561.
- [22] MAENTHAISONG, R., CHAIYAKUNAPRUK, N., NIRUNTRAPORN, S. & KONGKAEW, C. 2007. The efficacy of aloe vera used for burn wound healing: a systematic review. *burns*, 33, 713-718.
- [23] MAHMOUDI, M., MOHEBALI, M., IRANDOUST, H., HEJAZI, S., ABDOLI, H., SHIRANI-BIDABADI, L., MOAATAR, F., CHAREHDAR, S., SHAREGHI, N. & AKHAVAN, A. 2009. Therapeutic effects of propolis hydroalcoholic extract in the treatment of cutaneous leishmaniasis in Balb/c. *Journal of School of Public Health and Institute of Public Health Research*, 6, 19-26.
- [24] MARIMUTHU ALIAS ANTONISAMY, J., T, R. J. J. M., S, N. B., S, L. R., G, A. & T, R. J. J. E. 2012. Antibacterial and antifungal activity of aloe vera gel extract. *International Journal of Biomedical and Advance Research*, 3, 184-187.
- [25] MARQUELE, F. D., DI MAMBRO, V. M., GEORGETTI, S. R., CASAGRANDE, R., VALIM, Y. M. & FONSECA, M. J. V. 2005. Assessment of the antioxidant activities of Brazilian extracts of propolis alone and in topical pharmaceutical formulations. *Journal of pharmaceutical and biomedical analysis*, 39, 455-462.
- [26] MASHTOUB, S. 2017. Potential therapeutic applications for emu oil. *Lipid Technology*, 29, 28-31.
- [27] MEENA, A., KANDALE, A., RAO, M., PANDA, P. & KAUR, K. 2010. A Review on Leishmaniasis and treatment with natural drugs. *International Journal of Contemporary Research and Review*, 1, 1-5.
- [28] NAKAYA, M., ONDA, H., SASAKI, K., YUKIYOSHI, A., TACHIBANA, H. & YAMADA, K. 2007. Effect of royal jelly on bisphenol A-induced proliferation of human breast cancer cells. *Bioscience, biotechnology, and biochemistry*, 71, 253-255.
- [29] NICHOLAS, R., BERRY, V., HUNTER, P. A. & KELLY, J. A. 1999. The antifungal activity of mupirocin. *Journal of Antimicrobial Chemotherapy*, 43, 579-582.
- [30] NILFOROUSHZADEH, M., SHIRANI-BIDABADI, L., ZOLFAGHARI-BAGHBADERANI, A., SABERI, S., SIADAT, A. & MAHMOUDI, M. 2008. Comparison of *Thymus vulgaris* (Thyme), *Achillea millefolium* (Yarrow) and propolis hydroalcoholic extracts versus systemic glucantime in the treatment of cutaneous leishmaniasis in balb/c mice. *J Vector Borne Dis*, 45, 301-6.
- [31] NOORI, A., AL-GHAMDI, A., ANSARI, M. J., AL-ATTAL, Y. & SALOM, K. 2012. Synergistic effects of honey and propolis toward drug multi-resistant *Staphylococcus aureus*, *Escherichia coli* and *Candida albicans* isolates in single and polymicrobial cultures. *International journal of medical sciences*, 9, 793.
- [32] PARK, H. M., CHO, M. H., CHO, Y. & KIM, S. Y. 2012. Royal jelly increases collagen production in rat skin after ovariectomy. *Journal of medicinal food*, 15, 568-575.
- [33] POOVELIKUNNEL, T., GETHIN, G. & HUMPHREYS, H. 2015. Mupirocin resistance: clinical implications and potential alternatives for the eradication of MRSA. *Journal of Antimicrobial Chemotherapy*, 70, 2681-2692.
- [34] SABERI, S., MAHMOUDI, M., MOSAVI, Z., ARJMAND, R. & HEJAZI, S. H. 2013. Study on inhibitory activity of propolis alcoholic extract on opportunist fungi of candida in vitro. *Jundishapur Journal of Microbiology*.
- [35] SABERI, R., ZADEH, A.G., AFSHAR, M.J.A., FAKHAR, M., KEIGHOBADI, M., MOHTASEBI, S. and RAHIMI-ESBOEI, B., 2021. In vivo anti-leishmanial activity of concocted herbal topical preparation against *Leishmania major* (MRHO/IR/75/ER). *Annals of Parasitology*, 67, pp.483-488.
- [36] SENA-LOPES, A., BEZERRA, F. S. B., DAS NEVES, R. N., DE PINHO, R. B., SILVA, M. T. D. O., SAVEGNAGO, L., COLLARES, T., SEIXAS, F., BEGNINI, K. & HENRIQUES, J. A. P. 2018. Chemical composition, immunostimulatory, cytotoxic and antiparasitic activities of the essential oil from Brazilian red propolis. *PLoS One*, 13, e0191797.
- [37] SFORCIN, J., KANENO, R. & FUNARI, S. 2002. Absence of seasonal effect on the immunomodulatory action of Brazilian propolis on natural killer activity. *Journal of Venomous Animals and Toxins*, 8, 19-29.
- [38] SFORCIN, J. M., FERNANDES JÚNIOR, A., LOPES, C., FUNARI, S. & BANKOVA, V. 2001. Seasonal effect of Brazilian propolis on *Candida albicans* and *Candida tropicalis*. *Journal of Venomous Animals and Toxins*, 7, 139-144.
- [39] SHAHZAD, M. N. & AHMED, N. 2013. Effectiveness of Aloe Vera gel compared with 1% silver sulphadiazine

cream as burn wound dressing in second degree burns. *J Pak Med Assoc*, 63, 225-30.

[40] SHIRANI-BIDABADI, L., MAHMOUDI, M., SABERI, S., ZOLFAGHARI-BAGHBADERANI, A., NILFOROUSHZADEH, M., ABDOLI, H., MOATAR, F. & HEJAZI, S. 2009. The effectiveness of mix extracts of Thyme, Yarrow and Propolis on Cutaneous Leishmaniasis: a comparative study in animal model (Balb/c). *Tehran University Medical Journal*, 66, 785-790.

[41] SILICI, S. & KUTLUCA, S. 2005. Chemical composition and antibacterial activity of propolis collected by three different races of honeybees in the same region. *Journal of ethnopharmacology*, 99, 69-73.

[42] TAKEDA, K., NAGAMATSU, K. & OKUMURA, K. 2018. A water-soluble derivative of propolis augments the cytotoxic activity of natural killer cells. *Journal of ethnopharmacology*, 218, 51-58.

[43] TAVAKOLI, P., SHADDEL, M., YAKHCHALI, M., RAOUFI, N., SHAMSI, H. and DASTGHEIB, M. 2020. Antileishmanial effects of propolis against *Leishmania major* in vitro and in vivo. *Annals of Military and Health Sciences Research*, 18.

[44] WEAVER, M. & WEAVER, B. 2003. Draper's super bee apiaries-A unique Pennsylvania beekeeping business. *American Bee Journal*, 143, 459-463.

[45] ZEMSTOV, A., GADDIS, M. & MONTALVO-LUGO, V. M. 1996. Moisturizing and cosmetic properties of emu oil: a pilot double blind study. *Australasian Journal of Dermatology*, 37, 159-162.

[46] ZAHEDIFARD, F., LEE, H., NO, J.H., SALIMI, M., SEYED, N., ASOODEH, A. and RAFATI, S. 2020. Comparative study of different forms of Jellein antimicrobial peptide on *Leishmania* parasite. *Experimental parasitology*, 209, p.107823.